CHAPTER 73

Functional disorders of the intestine

Learning objectives

To recognise and understand:

- The spectrum of intestinal disorders resulting from abnormal neuromuscular functions
- The management of relatively common acute motility disturbances
- The management of common chronic disorders that present to surgeons such as chronic constipation and irritable bowel syndrome
- The existence of several rare neuromuscular diseases that may affect the intestine
- The limited role of surgery in the treatment of most of these disorders

APPLIED ANATOMY AND PHYSIOLOGY

The intestine must subserve basic functions of moving contents from proximal to distal in a rhythmical fashion to allow mixing, digestion and absorption of contents. The motility of the intestine has been studied for more than a century and all readers should know of the seminal experiments of Bayliss and Starling in their 1899 paper 'The movements and innervation of the small intestine', which led to adoption of the term 'peristalsis'. In the small intestine, fasting motility can be described by the three phases of the migrating motor complex (MMC), with fed activity resembling phase II. Colonic motility is much more complicated and still poorly understood with some features akin to the MMC but also specific phenomena such as retrograde movements (presumed to allow greater resident time and therefore fluid and electrolyte absorption). The main characteristics of intestinal motility are shown in ***Table 73.1***.

The intestine, like the heart, is autonomous in generating its own rhythmical electrical, and therefore local motor, activity by intrinsic pacemaker activity generated by small fibroblast-like cells called the interstitial cells of Cajal. These cells, which are mainly resident within the muscularis propria, have several key functions, including setting the membrane potential of smooth muscle cells so that they are primed to contract and connecting smooth muscle cells electrically so that synchronous

TABLE 73.1 Contractile activity of the intestine.

Region	Broad category	
Small intestine	Phase I	Quiescence (40–60% of total time)
	Phase II	High-frequency contractions allowing mixing and absorption (20–30% of total time)
	Phase III	High-amplitude propagated activity (5–10 minutes)
Large intestine	Phasic contractions	Low-amplitude propagated pressure waves
		High-amplitude propagated pressure waves[a]
		Retrograde pressure waves
		Simultaneous pressure waves
		Periodic colonic and rectal motor activity (localised bursts)
	Tonic contractions	Sustained activity responsible for tone

[a]Most akin to phase III of the migrating motor complex and responsible for mass movements of faecal content.

Sir William Bayliss, 1860–1924, physiologist, and **Ernest Henry Starling**, 1866–1927, University College London, London, UK. Starling's contributions to medicine also included Starling's principle (capillary pressures) and filling of the heart (Frank–Starling law).
Santiago Ramon y Cajal, 1852–1934, Spanish neuroscientist, pathologist and Nobel prize winner (1906) for studies of cellular anatomy of the nervous system.

contraction occurs. Also akin to the heart, this activity is affected by a hierarchy of external control systems but mainly by the enteric nervous system (ENS) via the myenteric plexus. The myenteric plexus is one of the two intramural plexuses of the ENS (the other being the submucosal plexus). The former has the major role in motor functions while the latter has roles in sensing, mucosal blood flow regulation and secretion. Both are composed of small groups of enteric neurones that congregate with glial cells to form ganglia, these being connected in a lattice-type network of axons (***Figure 73.1***). The ENS has a neurochemical complexity and number of neurones (five times the number in the spinal cord) that has led to it being called the 'little brain' (***Summary box 73.1***). Thus, although higher control mechanisms including the autonomic nervous system (ANS) and brain allow the intestinal motility to respond to wider environmental cues, e.g. waking, exercise, the smell and taste of food and stress, the intestine can initiate and sustain peristalsis without any external inputs.

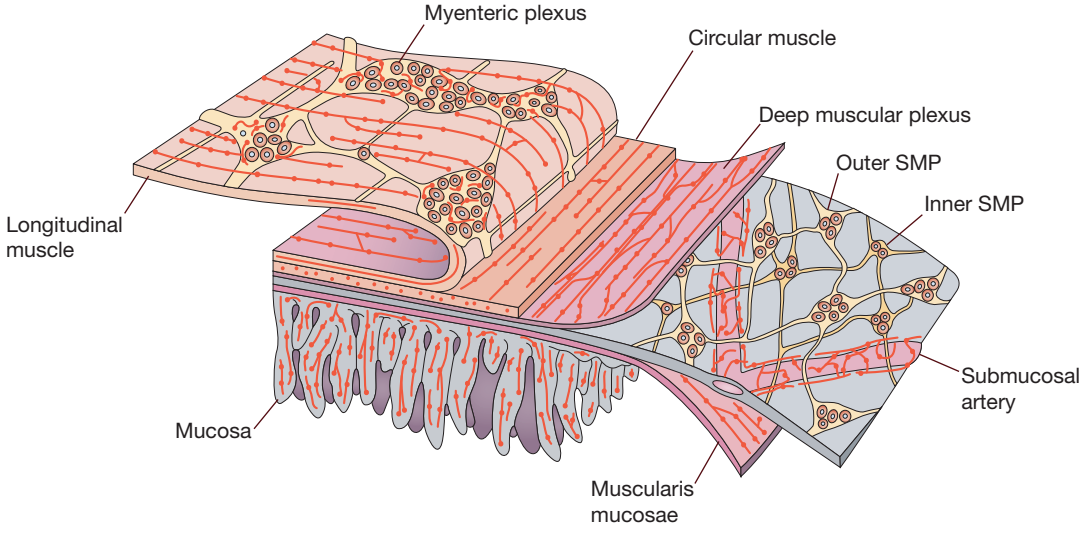

Figure 73.1 Schematic diagram of the enteric nervous system. SMP, submucosal plexus. (Reproduced by permission from Springer Nature. Furness JB. The enteric nervous system and neurogastroenterology. *Nat Rev Gastroenterol Hepatol* 2012; **9**: 286–94. © 2012.)

Summary box 73.1

Regulation of intestinal contractile activity

Myogenic control mechanisms

- Interstitial cells of Cajal generating slow wave activity

Neurogenic control mechanisms

- ENS (a variety of cells in myenteric and submucosal ganglia)
- ANS (sympathetic and parasympathetic mainly via ENS ganglia)
- Central nervous system (CNS) (brain–gut interactions)

Chemical control mechanisms

- Local paracrine (especially from mucosal enteroendocrine cells)
- Endocrine

The rectum constitutes a final and specialised end to the intestine. Its role is mainly for temporary storage of faeces prior to defecation. This role permits both further water absorption and the ability of higher mammals to socially defecate (an ability shared with small rodents as well as many larger species). To this end, the wall of the rectum is specialised in terms of compliance and of having nerve endings that provide conscious perception of filling. In concert with the upper anal canal, the rectum is also capable of distinguishing solid, liquid and gas by the 'sampling' reflex. Together the act of defecation requires complex neuromuscular functions and it is no surprise that it goes wrong with sufficient regularity to cause much human misery in the form of constipation and incontinence (see ***Chapter 80***).

TESTS OF INTESTINAL FUNCTION

Subsequent chapters address diagnostic tests specific to the rectum (see ***Chapter 79***) and anus (see ***Chapter 80***). Here the focus is on tests that may be relevant to studying the motility of the small intestine and colon. A general proviso in reading this section is that our current ability to understand the physiology of the intestine in humans is limited by both access and understanding. In general, we measure what can be measured and all tests have inherent limitations to interpretation. ***Summary box 73.2*** provides an overview of all tests, denoting those that have general clinical application versus those that are the preserve of highly specialised units or research studies.

Summary box 73.2 makes clear that few tests are in general use. Small bowel contrast studies, e.g. barium follow-through, although available, have poor sensitivity for detecting much other than visceral distension (superseded by axial imaging with computed tomography [CT] or MRI) or grossly retarded transit. Breath hydrogen testing assesses the presence

Summary box 73.2

Tests of small intestinal function

Transit

- Small bowel barium contrast study[a]
- Breath hydrogen small bowel transit tests (lactulose or lactose ^{13}C-ureide)[a]
- Wireless motility capsule small bowel transit study[b]

Contractile activity

- Antroduodenal manometry (ideally prolonged [24 hours] ambulatory study)
- Dynamic magnetic resonance imaging (MRI) studies

Tests of colonic function

Transit

- Radio-opaque marker studies[a]
- Isotope scintigraphy
- Wireless motility capsule whole-gut transit study[b]

Contractile activity

- Colonic manometry
- Dynamic MRI studies

[a]Denotes general availability.
[b]Adopted by some highly funded health systems.

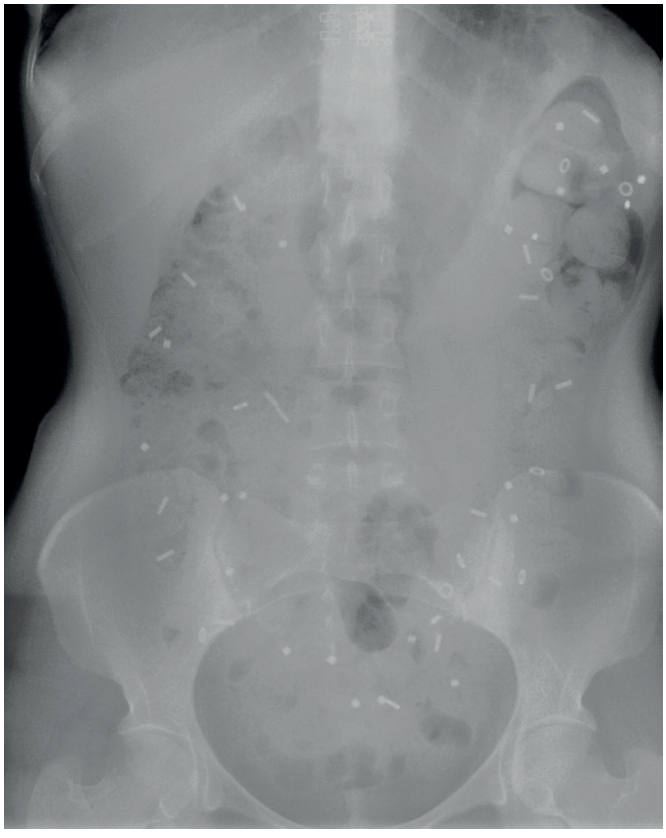

Figure 73.2 Radio-opaque marker transit study in a woman. All 50 markers are retained, indicating slow-transit constipation.

of carbohydrate malabsorption and is an indirect measure of transit because stagnated content allows some degree of bacterial overgrowth and fermentation products (hydrogen, methane and carbon dioxide). Although frequently used in patients with unexplained chronic abdominal symptoms such as irritable bowel syndrome (IBS), its utility in reliably measuring transit or detecting bacterial overgrowth is limited by issues of reproducibility.

The wireless motility capsule measures pH, temperature and pressure as it traverses the whole gastrointestinal tract; changes in these variables can be used to determine timings as it migrates from stomach to small bowel and large bowel. While it offers a number of advantages over and above current techniques, especially with respect to patient tolerability, safety and standardisation, it is not widely available owing to cost.

Prolonged measurement of small bowel contractile activity can be performed using multichannel pressure recordings called manometry that show phases of the MMC. Some findings may be indicative of underlying small bowel neuromuscular diseases such as myopathies and neuropathies (see ***Chronic impairment of intestinal motility with dilatation of the small intestine: intestinal pseudo-obstruction***) but these findings have issues of specificity and the technology itself is only available in a small number of centres worldwide. Dynamic MRI (long sequences of image acquisition with computer analysis) is currently a research tool but may well represent the future.

The radio-opaque marker study is the mainstay of evaluation of colonic transit. Though variations in technique exist in terms of the number of markers, interval to radiograph and definition of slow transit, the basic premise is that a number of markers (small pieces of plastic tubing, prepackaged in gelatin capsules) are ingested and an abdominal radiograph (which includes the pelvis) taken at an interval. The patient abstains from laxatives for the duration of the study. In patients with significant numbers of retained markers (based on control data), slow-transit constipation is diagnosed (***Figure 73.2***). Other studies of colonic transit, e.g. isotope scintigraphy and direct measurements of colonic contractile activity, are restricted to a very small number of specialist centres worldwide.

SCOPE OF DISEASE

A functional diagnosis is usually made when *routine* investigations fail to find an easy explanation (e.g. a structural or biochemical cause) for a combination of typical symptoms. For instance, in a patient with lower abdominal pain, constipation and bloating if routine investigation finds a morphological abnormality, e.g. sigmoid diverticulosis, then the patient will be given a diagnosis of diverticular disease. However, if all usual tests, including colonoscopy, yield no findings then the same patient might be described as having IBS – a functional intestinal disorder. Like much of medicine, there are however grey areas. Further, understanding is not aided by historic nomenclature where terms such as pseudo-obstruction describe different entities in the small and large intestine (***Table 73.2***). This chapter considers the main disorders using this classification with a focus on those most pertinent to the surgical reader.

TABLE 73.2 Scope of functional intestinal diseases.

History of onset	Visceral diameter	Region predominantly affected	Nomenclature
Acute	Dilated	Small intestine	Ileus (including postoperative ileus)
		Large intestine	Acute colonic pseudo-obstruction
Chronic	Dilated	Small intestine	Intestinal pseudo-obstruction
		Large intestine	Megacolon
Chronic	Normal	Intestine	Constipation and irritable bowel syndrome

ACUTE ADYNAMIC NEUROMUSCULAR STATES OF THE SMALL INTESTINE WITH DILATATION: ILEUS

Definition

Ileus can be defined as:

> ***a disruption of the normal propulsive ability of the intestine due to a malfunction of contractile activity in the absence of mechanical obstruction.***

This definition excepts certain older terms such as 'meconium ileus' and 'gallstone ileus' (see ***Chapters 17 and 78***) that persist in usage, although they are technically misnomers (i.e. there is mechanical obstruction). The term 'paralytic ileus', although descriptive for the student, is outdated and not entirely correct since studies show that motor activity is not abolished but rather dysregulated.

Causes and risk factors

The risk factors for ileus are listed in ***Summary box 73.3***. Postoperative ileus (POI) occurs in 10–20% of patients undergoing elective major abdominal surgery and is usually defined by a failure to tolerate oral intake or pass stool 72 hours after surgery.

Summary box 73.3

Risk factors for ileus

- Recent surgery: POI
- Local inflammation (peritonitis, severe acute pancreatitis)
- Systemic inflammation by any cause, e.g. sepsis, trauma
- Electrolyte disturbance (especially hypokalaemia and hypercalcaemia)
- Acute endocrine disturbance (hypothyroidism, diabetic ketoacidosis)
- Medications, e.g. opioids
- Acute CNS disease (especially high spinal transections)
- Intestinal ischaemia (mesenteric vascular disease)

Pathophysiology

Classic teaching points to a reflex inhibition of intestinal motility caused by deranged ANS inputs. This teaching, which fits nicely with basic 'fight and flight' concepts of increased sympathetic signalling and parasympathetic withdrawal during trauma (including surgery), has been superseded by the concept of a two-phase response. First, an immediate stress response, mediated by spinal reflexes and activation of the hypothalamic–pituitary–adrenal axis (HPA) axis, leads to a decrease or abolition of motility. This is then followed very rapidly by evolution of a more prolonged inflammatory response in the bowel wall itself, mediated first by mast cell activation and thence recruitment and activation of macrophages and neutrophils (***Figure 73.3***). These lead to inhibition of enteric neuronal and smooth muscle function as well as further effects on spinal reflexes.

Clinical features

Symptoms include abdominal distension and vomiting akin to mechanical small bowel obstruction (see ***Chapter 78***); however, colicky pain is less of a feature. On examination, other than evidence of the cause, e.g. recent surgery, the abdomen will be distended, tympanic and have reduced or absent bowel sounds.

Diagnosis

CT scanning is frequently required to exclude both mechanical obstruction and any local driver of ileus in the peritoneum such as inflammation or infection (***Figure 73.4***). In instances of POI this is required to exclude local complications of surgery. Blood tests should be used to detect any drivers of ileus such as metabolic abnormalities (especially hypokalaemia).

Management

Ileus may be managed by nasogastric drainage and restriction of oral intake until there is evidence of improvement. Supportive care such as attention to fluid and electrolyte balance and nutrition is also important, especially if ileus persists. Underlying drivers of ileus, e.g. abscess or peritonitis, should be managed on their merits. Regrettably, despite improved knowledge of the pathophysiology, specific drugs aimed at blocking inflammation or stimulating local neuromuscular function, e.g. prokinetics, have not proved sufficiently effective yet to be adopted for routine use.

In patients with POI, if prolonged, CT scanning is the most effective investigation; it will demonstrate any intra-abdominal sepsis or mechanical obstruction and therefore guide any

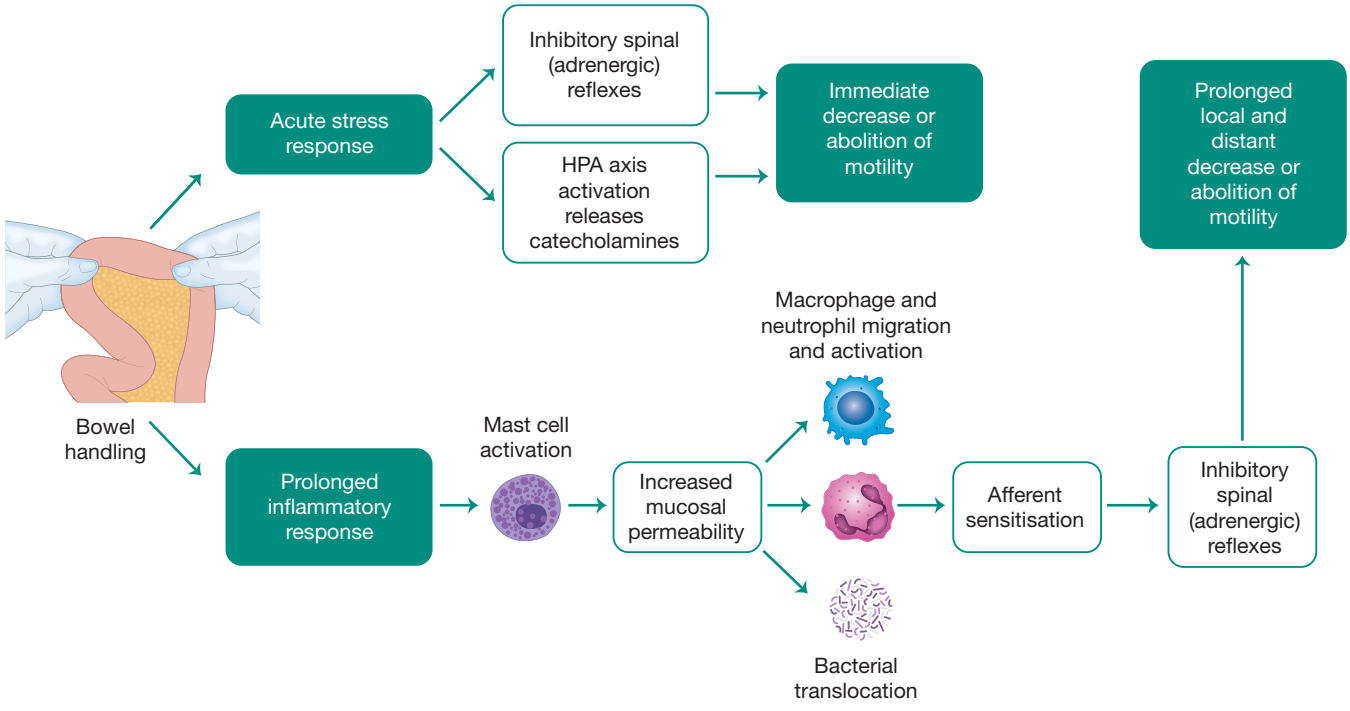

Figure 73.3 Pathophysiology of postoperative ileus. HPA, hypothalamic–pituitary–adrenal axis.

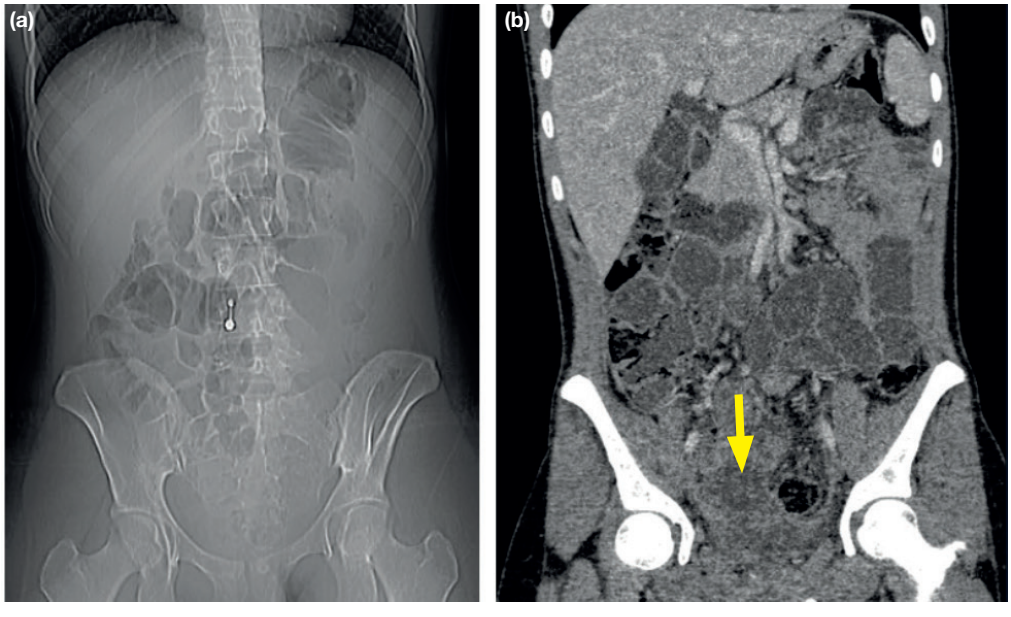

Figure 73.4 Computed tomography abdomen scout film **(a)** and representative coronal image **(b)** of a 22-year-old woman showing widespread dilatation of the small intestine (ileus) secondary to a driving inflammatory focus (pelvic collection, arrow) (courtesy of Dr Arman Parsai, Barts Health NHS Trust, London, UK).

requirement for laparotomy. Otherwise the decision to take a patient back to theatre in these circumstances is always difficult. The need for a laparotomy becomes increasingly likely the longer the bowel inactivity persists, particularly if it lasts for more than 7 days or if bowel activity recommences following surgery and then stops again.

Prevention

Minimally invasive surgical approaches have reduced risks of POI for many operations. The enhanced recovery programme (see ***Chapter 74***) seeks to further reduce risk of POI by avoidance of opioid-containing drugs and suppression of the inflammatory response.

ACUTE ADYNAMIC NEUROMUSCULAR STATES OF THE LARGE INTESTINE WITH DILATATION: ACUTE COLONIC PSEUDO-OBSTRUCTION

Definition

The term acute colonic pseudo-obstruction (ACPO) is defined as:

> ***Acute massive dilatation of the colon with obstructive symptoms but in the absence of mechanical obstruction.***

ACPO was first described by Sir William Ogilvie, who in 1948 recognised this syndrome in two patients with sudden onset of abdominal pain, constipation and large bowel dilatation (hence the eponym Ogilvie's syndrome). It is one of the three common diagnoses in patients evaluated for a clinical presentation of large bowel obstruction (see ***Chapter 78***), the other two being colorectal cancer and volvulus (remember the three Ts: tumour, torsion and 'tired out'). Toxic megacolon (see ***Chapter 75***), although conveniently being a fourth 'T', should be considered as a different condition entirely although the end point is also one of acute dilatation.

Risk factors

In Ogilvie's original report, the clinical picture was associated with a retroperitoneal neoplasm infiltrating and destroying prevertebral ganglia. This is actually a very rare cause. The main risks are shown in ***Summary box 73.4***.

Summary box 73.4

Risk factors for acute colonic pseudo-obstruction

- Frailty and senility
  - Neurological
  - Neurodegenerative diseases
  - Stroke
  - Spinal cord injury
  - Retroperitoneum tumour infiltration
- Trauma/surgical
  - Major orthopaedic injuries or surgery, e.g. vertebral, pelvic and femoral
  - Major gynaecological surgery
  - Obstetrics, including caesarean section
- Systemic inflammation by any cause, e.g. sepsis, trauma, especially with multiorgan failure
- Localised infective conditions, e.g. respiratory, urinary
- Myocardial infarction
- Metabolic and electrolyte disturbances
- Medications, e.g. opioids and any with anticholinergic actions (e.g. psychiatric and Parkinson's), calcium channel antagonists

The majority of patients fall into two categories: those that have a high background risk and a small acute event (e.g. the elderly patient with Parkinson's disease and a urinary tract infection [UTI]) – the colon has little 'reserve' and a small insult tips the balance into one of progressive abolition of motility and tone with consequent gaseous dilatation; and those with little background risk and a large acute event, e.g. major surgery/trauma.

Pathophysiology

This is poorly understood. It can however be appreciated that, like ileus, risk factors reflect both 'imbalanced' extrinsic autonomic innervation and an 'inflammatory' state. Evidence to support the former is provided by the response to anticholinesterase pharmacological therapy.

Clinical features

Symptoms include abdominal distension, absolute constipation and, as a later feature, vomiting akin to mechanical large bowel obstruction (see ***Chapter 78***); however, colicky pain is less of a feature. The history is very important to establish risk factors, some of which may be modifiable. On abdominal examination, the abdomen is usually grossly distended and tympanic. In uncomplicated cases, the abdomen should not be tender. Tenderness and especially any evidence of peritonism indicate that massive colonic dilatation may have led to ischaemia with/without perforation – a surgical emergency. Such complications occur in 3–15% of patients with advanced age and increased caecal diameter, with a delay in decompression increasing risk.

Diagnosis relies upon accurate clinical observation and plain abdominal radiography showing degrees of colonic dilatation, mainly involving the proximal colon. CT is however the definitive investigation (***Figure 73.5***) to differentiate mechanical from pseudo-obstruction, to provide a caecal diameter and to show any evidence of complications (e.g. perforation). A CT scan will also differentiate pseudomembranous colitis with toxic dilatation, which is a further differential diagnosis in hospitalised or institutionalised patients due to *Clostridium difficile* infection.

Management

The management of ACPO depends on whether complications are evident or considered imminent. In patients with clinical and radiological features of caecal ischaemia or perforation, emergency surgery will be required and usually necessitates a subtotal colectomy and end ileostomy (with high levels of morbidity and mortality). The majority of patients can however follow a more stepwise approach, starting with conservative measures (***Table 73.3***). Clearly the underlying cause where relevant, e.g. UTI, respiratory tract infection or myocardial infarction, should also be managed in parallel. It is reasonable to wait before progressing from one stage to the

Sir William Heneage Ogilvie, 1887–1973, surgeon, Royal Army Medical Corps (First World War), Oxford, and Guy's Hospital, London, UK.
James Parkinson, 1755–1824, general practitioner of Shoreditch, London, UK, published 'An essay on the shaking palsy' in 1817.

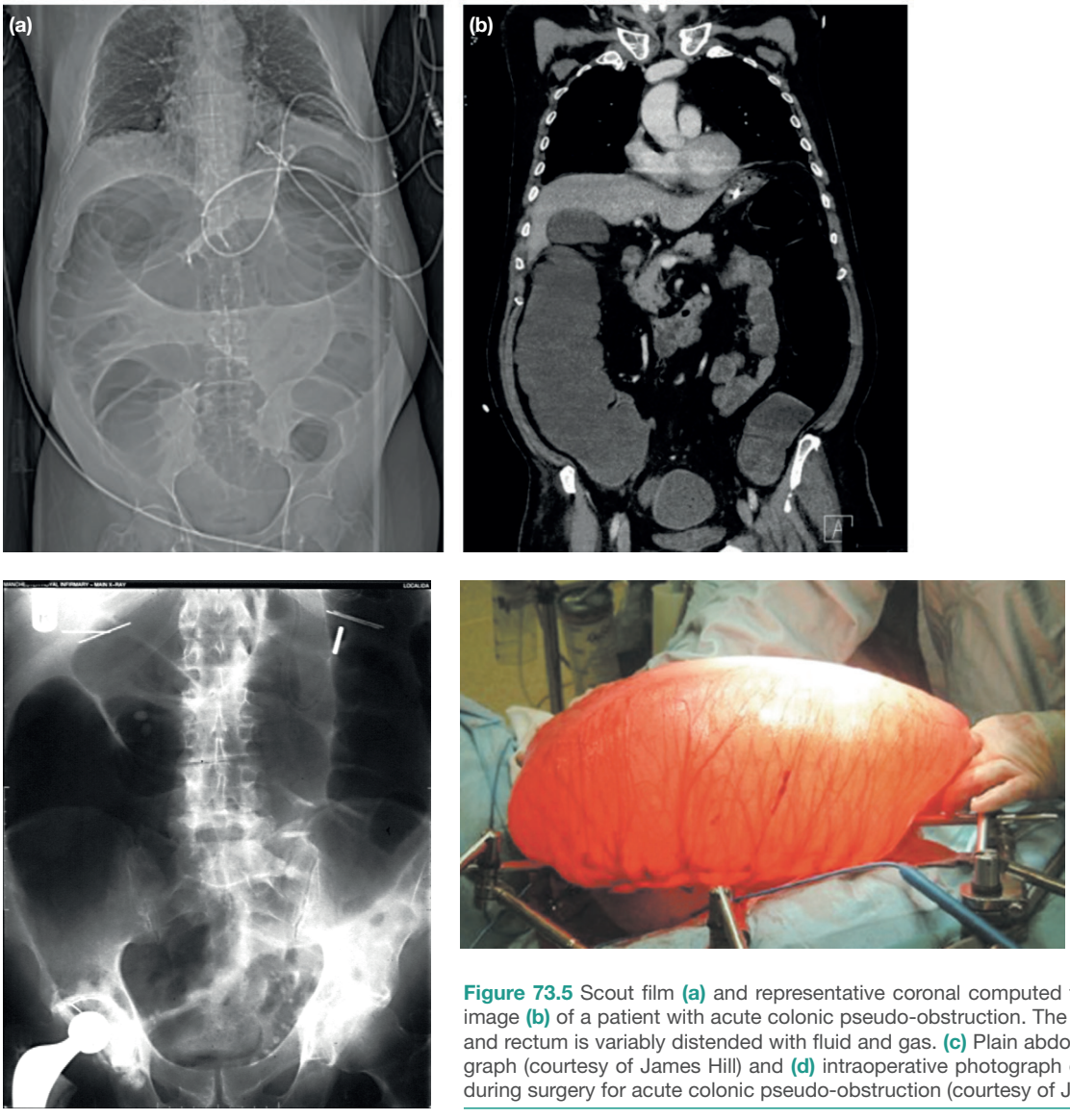

Figure 73.5 Scout film **(a)** and representative coronal computed tomography image **(b)** of a patient with acute colonic pseudo-obstruction. The entire colon and rectum is variably distended with fluid and gas. **(c)** Plain abdominal radiograph (courtesy of James Hill) and **(d)** intraoperative photograph of the colon during surgery for acute colonic pseudo-obstruction (courtesy of James Hill).

TABLE 73.3 Management of acute colonic pseudo-obstruction.

Reversal of risk factors	Correct fluid and electrolyte imbalances
	Stop or reduce offending drugs, e.g. opioids, anticholinergics, calcium channel blockers (where possible)
	Empty the rectum by enemas and/or flatus tube
Endoscopic decompression	Colonoscopy +/– flatus tube
Pharmacological decompression	Intravenous neostigmine unless contraindicated (risk of arrhythmia and bronchospasm[a])
Surgery	Subtotal colectomy (usually with ileostomy)
	Venting stoma, e.g. caecostomy, in very unfit patients

[a]Requires high-dependency unit-level monitoring and support on hand for cardiorespiratory complications.

next but caecal diameters of 12 cm or above warrant rapid decompression to reduce perforation risk.

The decision of whether to use intravenous neostigmine is difficult and is usually reserved for patients in whom supportive measures and colonic decompression have failed. Treatment is associated with profound autonomic effects (salivation, bradycardia, bronchospasm and hypotension) as well as abdominal cramps, followed often by a massive evacuation of flatus and faeces. Cardiac monitoring and a health professional competent in the emergency administration of resuscitative drugs (especially atropine) are essential. Contraindications to the use of neostigmine include renal insufficiency, recent myocardial infarct, arrhythmias and asthma.

Surgery is associated with high morbidity and mortality and should be reserved for those with impending perforation when other treatments have failed or perforation has occurred.

Prognosis

ACPO is a life-threatening condition in which prompt diagnosis and appropriate management can limit the occurrence of complications (e.g. ischaemia or perforation). Such complications occur in about 5–10% of patients and require emergency surgery with mortality rates between 30% and 60%. Recurrence is an issue in some patients with unmodifiable risk factors, e.g. senility and neurological disease. Such patients should have chronic modification of polypharmacy to avoid offending drugs and keep the rectum empty by regular enemas. Prokinetic medications, such as those used for chronic constipation, may have a role in such patients, although none are licensed for this indication.

CHRONIC IMPAIRMENT OF INTESTINAL MOTILITY WITH DILATATION OF THE SMALL INTESTINE: INTESTINAL PSEUDO-OBSTRUCTION

Definition

Intestinal pseudo-obstruction (IPO) is defined as:

> ***A clinical syndrome caused by severe impairment of intestinal motility leading to small intestinal dilatation in the absence of a mechanical cause.***

The term 'chronic' is sometimes added for clarity.

Causes

IPO is a rare disease. Approximately half of cases arise shortly after birth or in infancy, caused by a number of very rare enteric neuropathies and myopathies, including genetic and familial, inflammatory and degenerative forms. Other cases arise later in life when a secondary aetiology is more common. In some patients, a cause is not found and these are termed idiopathic. The full list of causes is given in ***Summary box 73.5***.

Summary box 73.5

Causes of intestinal pseudo-obstruction

Primary

- Several very rare enteric myopathies and neuropathies
- Unknown (termed 'idiopathic')

Secondary

- Connective tissue disease, especially scleroderma
- Radiation injury
- Amyloidosis
- Autonomic neuropathies including diabetes and paraneoplasia
- Infections: Chagas' disease (South American trypanosomiasis)

Diagnosis

IPO presents clinically with the symptoms and signs of small bowel obstruction with pain, distension and vomiting. After clinical evaluation and plain radiology, a degree of suspicion is helpful to avoid unnecessary and potentially harmful surgery. Such suspicion is merited when there is no obvious cause for mechanical obstruction, i.e. no known bowel disease, previous surgery or hernia, and on the length of history. Here, knowing the list of secondary causes becomes helpful. For instance, in someone who is a smoker with finger clubbing, a small cell carcinoma of the lung may be the cause of paraneoplastic pseudo-obstruction; alternatively, the patient may have clinical signs of scleroderma. Axial imaging is essential to exclude mechanical obstruction. Adjunctive blood and imaging tests may help define a cause and these can include MRI of the brain and skeletal muscle biopsy for rare diagnoses such as mitochondrial myopathies.

Primary neuropathies and myopathies can be diagnosed histologically, but this requires full-thickness tissue and a variety of special stains (available only in specialist centres). Since laparotomy and bowel resections are best avoided, a laparoscopic or minilaparotomy full-thickness biopsy may be warranted for diagnosis (***Figures 73.6 and 73.7***).

Management

The main lines of management are shown in ***Summary box 73.6***, noting that for most patients there is no cure. Surgery, with the exception of placing feeding tubes or formation of a venting stoma, is impotent for a condition that is a diffuse neuromuscular disease. Further, surgery worsens the prognosis by adding the risk of adhesions into the diagnosis and, if resections or complications occur, speeding the patient towards intestinal failure. Small bowel (or multivisceral) transplantation is an option in selected patients.

Figure 73.6 Intestinal pseudo-obstruction in a young male patient. A full-thickness biopsy was undertaken from the proximal jejunum at minilaparotomy.

Carlos Justiniano Ribeiro Chagas, 1879–1934, Director of the Oswaldo Cruz Institute and Professor of Tropical Medicine, University of Rio de Janeiro, Brazil.

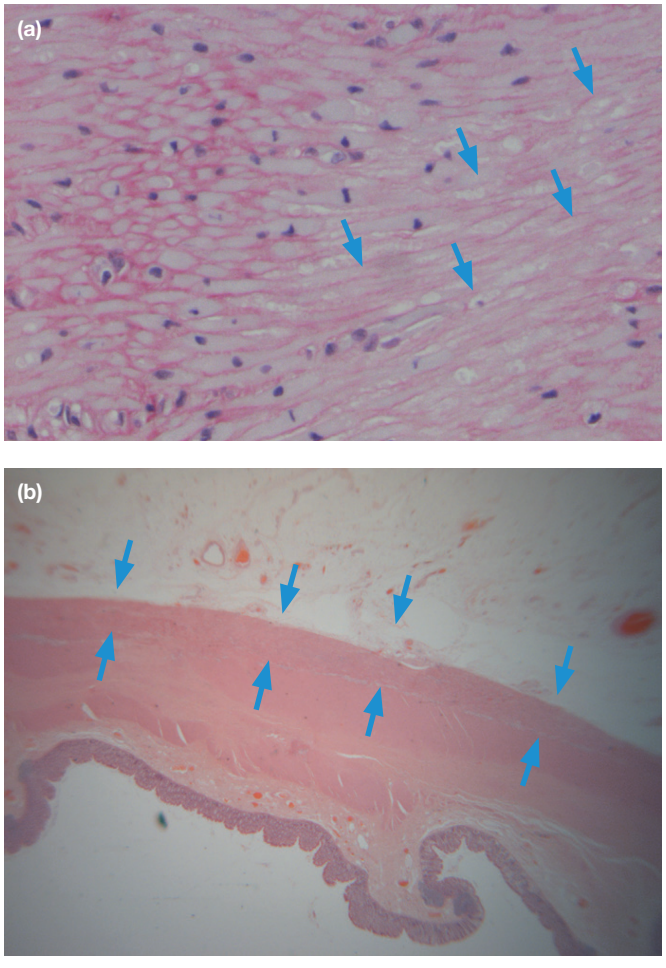

Figure 73.7 Two examples of myopathy: **(a)** hollow visceral myopathy (note the vacuolation of the smooth muscle, arrows); **(b)** extra muscle layer in the muscularis propria (arrows).

Summary box 73.6

Management of intestinal pseudo-obstruction

- Nutrition (enteral/parenteral)
- Analgesia (but try to avoid opioids)
- Prokinetics (generally disappointing)
- Antibiotics (overgrowth)
- Immunotherapy – specific inflammatory cases (limited data)
- Psychological support, including specific patient support groups
- Palliative care
- Surgery (very selected cases)

Prognosis

Prognosis is poor – sometimes considered the 'motor neurone disease' of the gut. Infantile forms have a mortality of approximately 50%. This is generally lower in adult forms depending on cause and avoiding repeated surgery and overuse of opioid drugs. Together these cause a vicious spiral of declining motility and progression to type II/III intestinal failure with the need for lifelong parenteral nutrition.

CHRONIC IMPAIRMENT OF INTESTINAL MOTILITY WITH DILATATION OF THE LARGE INTESTINE: MEGACOLON AND MEGARECTUM

Definition

Chronic dilatation in the absence of a mechanically obstructing cause can be focused in the colon (megacolon) or rectum (megarectum), although in practice these commonly overlap (***Figure 73.8***). Megacolon may also accompany some forms of IPO in patients found to have chronic small and large intestinal dilatation. Toxic megacolon refers to an acute condition in which acute inflammation leads to a loss of compliance and rapid dilatation (it has nothing in common other than the name).

Causes of megacolon and megarectum

Primary and secondary causes (***Table 73.4***) vary between megarectum and megacolon. The most common disease to use the term megacolon is Hirschsprung's disease (occurring in 1 in 5000 live births) (see ***Chapter 17***). Actually, in this instance, it can be argued that the so-called 'congenital megacolon' does in fact reflect a degree of distal obstruction from the distal contracted aganglionic segment. This leads to the absence of passage of meconium at birth and is generally incompatible with life without urgent surgery. Adult Hirschsprung's disease is a very rare disease and leads to a megarectum because the affected segment is 'ultrashort', affecting only the transition zone of the anus. Histologically, this is very difficult to diagnose with certainty and some challenge its existence at all.

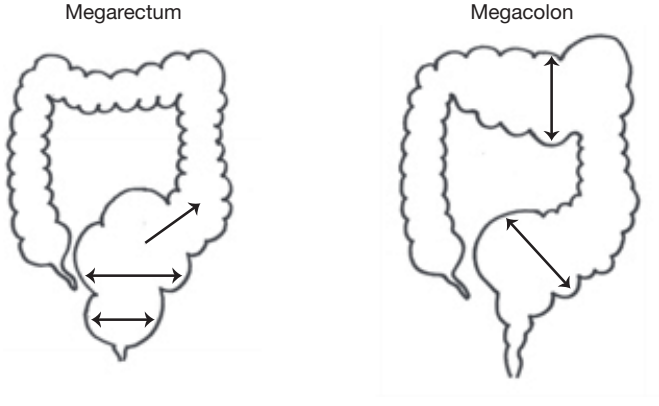

Figure 73.8 Schematic drawing of the distribution of bowel dilatation in megacolon and megarectum.

Harald Hirschsprung, 1830–1916, physician, The Queen Louise Hospital for Children, Copenhagen, Denmark, described congenital megacolon in 1887.

TABLE 73.4 Causes of megacolon and megarectum.

Megacolon	*Primary*	Congenital	Classic (rectosigmoid) Hirschsprung's disease
			Rare early-onset (some genetic) myopathies and neuropathies
		Acquired	Rare late-onset (some genetic mitochondrial) myopathies and neuropathies
			Unknown (termed 'idiopathic')
	Secondary	Genetic	Muscular dystrophy and other rare genetic muscle diseases
			MEN type 2B with ganglioneuromatosis
			Rare genetic autonomic neuropathies
		Acquired	CNS diseases, including senility, Parkinson's, dementias, amyloid and spinal cord injury
			Connective tissue disease, especially scleroderma
			Infections: Chagas' disease (South American trypanosomiasis)
			Autonomic neuropathies secondary to diabetes and paraneoplasia
Megarectum	*Primary*	Congenital	Ultrashort-segment Hirschsprung's disease (congenital megarectum)
			Inadequately resected Hirschsprung's disease (post reconstruction)
			Anorectal malformations (post reconstruction)
	Secondary	Congenital	Severe psychobehavioural + cognitive impairment (+ genetic)
		Acquired	Later-onset behavioural (autistic spectrum) disorders
			Sexual abuse; neglect; parental negativism

CNS, central nervous system; MEN, multiple endocrine neoplasia.

More common causes of megacolon include extreme senility and CNS neurodegenerative disease, resembling an attenuated form of ACPO. Others are denoted 'idiopathic' to reflect that no cause is established; this group, who are predominantly female, phenotypically resemble a severe form of slow-transit constipation (see ***Constipation***). All are rare.

Patients with megarectum are usually divided into two groups by clinicians. The first are those who have had previous surgery for Hirschsprung's disease or anorectal malformations in whom ongoing problems are common – due perhaps to surgical reconstruction or an as yet undetermined neuromuscular disease. The second, predominantly male, group are sometimes described as 'idiopathic'; however, nearly all, if assessed carefully, will have some form of psychobehavioural disorder. The pathogenesis is considered to be stool withholding in infancy or childhood, leading to chronic distension and loss of compliance.

Diagnosis and management

Megarectum may present with a mass the size of a full-term baby (***Figure 73.9***) but diagnosis is mainly radiological. The mainstay of management of both (in brief) requires getting the rectum empty. In some patients with megarectum this may require manual disimpaction under anaesthesia. Thereafter, high doses of regular osmotic and simulant laxatives orally as well as regular enemas (or high-volume transanal irrigation (TAI); see ***Constipation***) are required to keep it empty. Prokinetics may also have a role. Compliance with medication is often an issue in young patients with psychobehavioural problems. Surgery has an important role in patients who fail medical management. Colectomy or subtotal colectomy is generally required for megacolon. A variety of options exist for megarectum. A first step may be an anterograde colonic enema (ACE) procedure (see ***Constipation***). If this fails, definitive surgery includes pull-through procedures, low anterior resection, restorative proctocolectomy and rectum-reducing procedures, e.g. vertical reduction rectoplasty. All should be undertaken with covering loop ileostomy and many advocate performing an ileostomy for 6 months to 1 year prior to surgery. This allows the rectum to shrink and reduce in vascularity, making eventual surgery safer; some patients may also simply

Figure 73.9 Plain abdominal radiograph of a teenage male with megarectum.

choose to live with the ileostomy rather than risk pelvic surgery. The hazard of operating on a rectum that occupies the whole pelvis with serosal veins that sometimes resemble the iliac veins cannot be underestimated and surgery should be performed in specialist centres.

CHRONIC IMPAIRMENT OF INTESTINAL MOTILITY WITHOUT DILATATION

Constipation and IBS are very common conditions and collectively represent about a third of patients presenting to the average colorectal clinic in the Western world. They are presented here as separate entities to reflect the general approach of most physicians; however, the reader should be aware that there is very considerable overlap, especially between constipation and the constipation-predominant form of IBS (C-IBS). Patients can fulfil the criteria for both diagnoses concurrently or move between diagnoses over time.

Constipation

Definitions

'Constipation' is not a disease but rather a term often used by patients to describe dissatisfaction with their bowel function or their ability to defecate. As such it means different things to different patients (and different doctors) and can describe symptoms that directly relate to defecation, e.g. straining, or those considered consequent in the abdomen, e.g. pain and bloating. More formal definitions such as that of the American College of Gastroenterologists – 'unsatisfactory defecation, characterized by infrequent stools, difficult stool passage or both for at least 3 months' – cover most symptoms and introduce a time criterion to exclude patients with transient symptoms (sometimes called 'simple constipation'). Stricter definitions of 'chronic constipation' include a measure of resistance to treatment – 'unsatisfactory defecation characterized by infrequent stools, difficult stool passage or both for at least 6 months where this has proven unresponsive to lifestyle alterations and basic laxative therapy'.

Epidemiology

Self-reported constipation is very common, with a worldwide prevalence of about 10% (making it one of the commonest ailments in humans). Fortunately, patients with chronic constipation (based on 6 months of symptoms and failure of at least two laxatives) are much less common (approximately 0.5%). Most studies report a higher prevalence of self-reported constipation in women than in men with a ratio of 2:1. The ratio is much higher for chronic constipation at approximately 9:1 female to male.

Risk factors

The vast majority of patients with chronic constipation lack a single unifying cause for their problems. The main associated medical conditions and diseases within the gastrointestinal tract itself are listed in *Table 73.5*.

Diagnosis

Clinical history

A thorough history will determine whether constipation represents a new complaint, i.e. one indicative of a change

TABLE 73.5 Risk factors for constipation.

Gastrointestinal causes	
Mechanical obstruction	Benign and malignant strictures
Functional obstruction	Pelvic organ prolapse syndromes (dynamic obstruction at the level of the anorectum)
	Megarectum
	Anal pain, e.g. chronic fissure
Medical causes	
Metabolic disorders	Hypercalcaemia, uraemia, hypokalaemia, hypomagnesaemia
Endocrine disorders	Hypothyroidism, diabetes, pregnancy
Neurological disorders	Degenerative CNS diseases, e.g. multiple sclerosis, Parkinson's, cerebrovascular disease, spinal or pelvic nerve lesions, autonomic neuropathies, cognitive impairment
Drugs	Opioids
	Anticholinergics
	Calcium channel blockers
Psychological	Severe endogenous depression
	Eating disorders
	Cognitive behavioural disorders
Other	Connective tissue diseases
	Joint hypermobility
	Causes of immobility, e.g. degenerative joint disease

CNS, central nervous system.

in bowel habit. The patient should be asked specifically about the frequency and consistency of bowel movements and the progress of such changes over time (as well as other alarm symptoms such as rectal bleeding and weight loss). With additional information regarding family history, previous colon cancer screening and other gastrointestinal investigations, an informed decision can be made whether intraluminal investigation of the colon is required. Other organic causes of constipation may be deduced by appropriate history taking and biochemical investigation. With the exclusion of treatable secondary causes, if the history is short and multiple previous therapies have not already been tried, the patient may be first considered to have 'simple' constipation that can be managed with reassurance and lifestyle advice (fibre, fluids and exercise) with/without simple laxative therapy.

In patients with chronic symptoms, after exclusion of a secondary cause, the focus should shift to the investigation and management of chronic constipation. Many patients may attribute the start of symptoms to a major life event. Common among these are hysterectomy and childbirth, other abdominal surgeries or trauma. Constipation can also be associated with previous abuse and it may sometimes be necessary to tactfully seek a history of physical or sexual abuse. Other patients will have no such triggers, having had symptoms from childhood and on occasion from infancy. Such patients are overwhelmingly female (>95%) and on investigation are often found to have generalised slow-transit constipation as opposed to other pathophysiological findings (this group, who represent 5–10% of patients with chronic constipation, are variably referred to in the literature are 'idiopathic slow-transit constipation' or 'colonic inertia'). It is helpful to systematically document the main symptoms that in the patient's mind constitute a problem since this has some bearing on treatment decisions and subsequent monitoring of effectiveness. Several questions form detailed scoring systems to systematically facilitate this in a research context. However, in routine practice it is sufficient to list in the patient's record the presence or absence of several common symptoms (***Summary box 73.7***). The presence of prolapse symptoms reflects the overlap between diagnoses in patients with pelvic floor disorders (see ***Chapter 80***). The remaining history should document prescribed and self-administered laxatives (and therapeutic benefit thereof) and also gain an impression of the quality of diet in respect of fibre and fluid intake.

Summary box 73.7

Symptoms to directly question in patients with constipation

Abdominal symptoms
- Abdominal pain
- Bloating

Defecatory symptoms
- Frequency of spontaneous or assisted bowel opening
- Painful defecation
- Stool consistency (can use Bristol stool scale)
- Digitation (vaginal or anal)
- Straining
- Incomplete/unsuccessful evacuation
- Leakage/incontinence
- Prolapse

Other pelvic symptoms
- Vaginal bulging or prolapse
- Urinary incontinence

Clinical examination

Poor nutritional status should prompt a search for a secondary cause, including occult carcinoma, more widespread intestinal motility disorders such as IPO (see ***Chronic impairment of intestinal motility with dilatation of the small intestine: intestinal pseudo-obstruction***) and eating disorders. An abdominal examination should be conducted to look for scars, any significant abdominal distension, tenderness or masses. Bloating is a common and expected finding with chronic constipation, but significant distension, tenderness or masses should prompt a full investigation.

All patients presenting with constipation should undergo a rectal examination. The perineum and anus should be examined for evidence of faecal incontinence that may indicate impaction and overflow. Some degree of faecal incontinence and chronic constipation coexists in 40% of patients; marked soiling of the underwear is especially associated with the rarer diagnosis of megarectum. Scarring, e.g. from episiotomy, sentinel pile formation secondary to an underlying anal fissure, external haemorrhoids or prolapse, may also be present. The degree of perineal descent on straining, indicative of pelvic floor weakness, should also be determined visually (>3 cm is usually considered abnormal). A digital rectal examination will diagnose impaction, gain a rough measure of anal tone at rest and on squeeze and ascertain obvious sphincter defects. An effort should be made to look for any anterior defect in the rectovaginal septum leading to a rectocele. Anoscopy and proctoscopy should be performed if there is any history of rectal bleeding and may indicate fissure or internal piles. A urogynaecological examination is desirable in all patients with suspected pelvic multi-organ prolapse.

Investigations

While findings from history or physical examination may indicate a secondary cause of constipation, making further investigation mandatory, it is also typical practice in patients with chronic constipation to exclude certain secondary causes by investigation even though the diagnostic utility of such investigations is acknowledged to be low (the commonest undiagnosed systemic disease is hypothyroidism). Thus, serum electrolyte, creatinine, calcium, glucose, haemoglobin levels and thyroid function tests are usually performed. The approach taken to structural investigation of the colon when patients have no suspected intraluminal pathology varies on the basis of available resource and may include colonoscopy.

In patients with chronic constipation in whom basic laxatives have failed, further specialist investigative tests may be warranted. Colonic transit can be investigated by a radio-opaque marker study (***Figure 73.2***). In addition, rectal

sensory testing and evacuation proctography will determine if the patient has a functional or dynamic structural cause of evacuation disorder. Problems such as dyssynergic defecation (functional) and intussusception/rectocele (structural) may occur in isolation or coexist with transit disturbances (*Figure 73.10*).

Management

The treatment of chronic constipation follows a stepwise progression from lifestyle changes through potentially to major surgery in a small minority of patients. *Table 73.6* lists the main available approaches, noting where some apply only to certain diagnoses derived from the results of specialist tests of colonic and anorectal function. *Figure 73.11* provides a basic algorithm to accompany *Table 73.6*.

Patients with chronic constipation have generally had symptoms for many years and will have tried a number of remedies and prescribed laxatives. They will also usually have tried to address lifestyle modifications. Before resorting to specialist tests, it is possible to try and rationalise laxative therapy and provide a programme of nurse-led behavioural interventions. In regard to laxatives, current advice is to stop current laxatives (unless these are working well) and then titrate an oral osmotic laxative, e.g. polyethylene glycol (PEG), until the stool form is soft or liquid. If this is insufficient then a stimulant laxative such as bisacodyl may be added. If symptoms of obstructed defecation predominate then rectal laxatives in the form of suppositories or enemas may be tried with or without continuation of oral laxatives. The failure of such drugs should then prompt a trial of one of the newer prokinetic or secretagogue

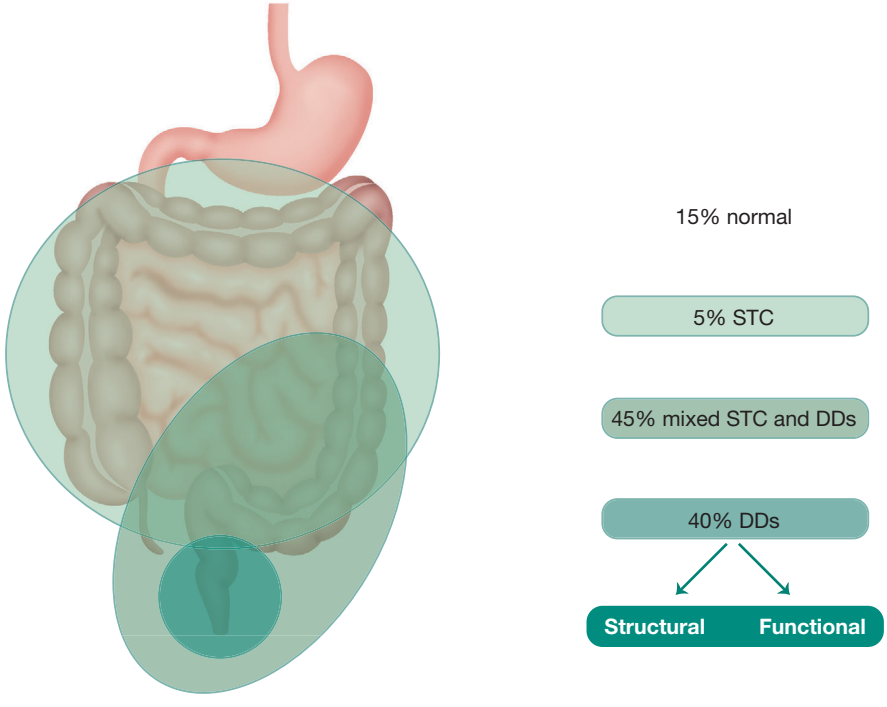

Figure 73.10 Schematic overview of pathophysiology of chronic constipation. DD, defecation disorder; STC, slow-transit constipation.

TABLE 73.6 Treatment options in patients with chronic constipation.

Lifestyle	Increase fluid intake
	Dietary modification, e.g. increased fibre
	Increase exercise
	Reduce body mass (pelvic floor prolapse syndromes)
Drugs	Oral laxatives (favoured for slow transit)
	Rectal laxatives (favoured for rectal evacuation disorders)
	Prokinetics, e.g. prucalopride
	Secretagogues, e.g. linaclotide
Behavioural therapies	Habit training
	Habit training with direct visual biofeedback (favoured for dyssynergic defecation)
	Pelvic floor muscle training (favoured for pelvic floor prolapse syndromes)
Transanal irrigation	High- or low-volume systems available
Surgery	See *Summary box 73.8*

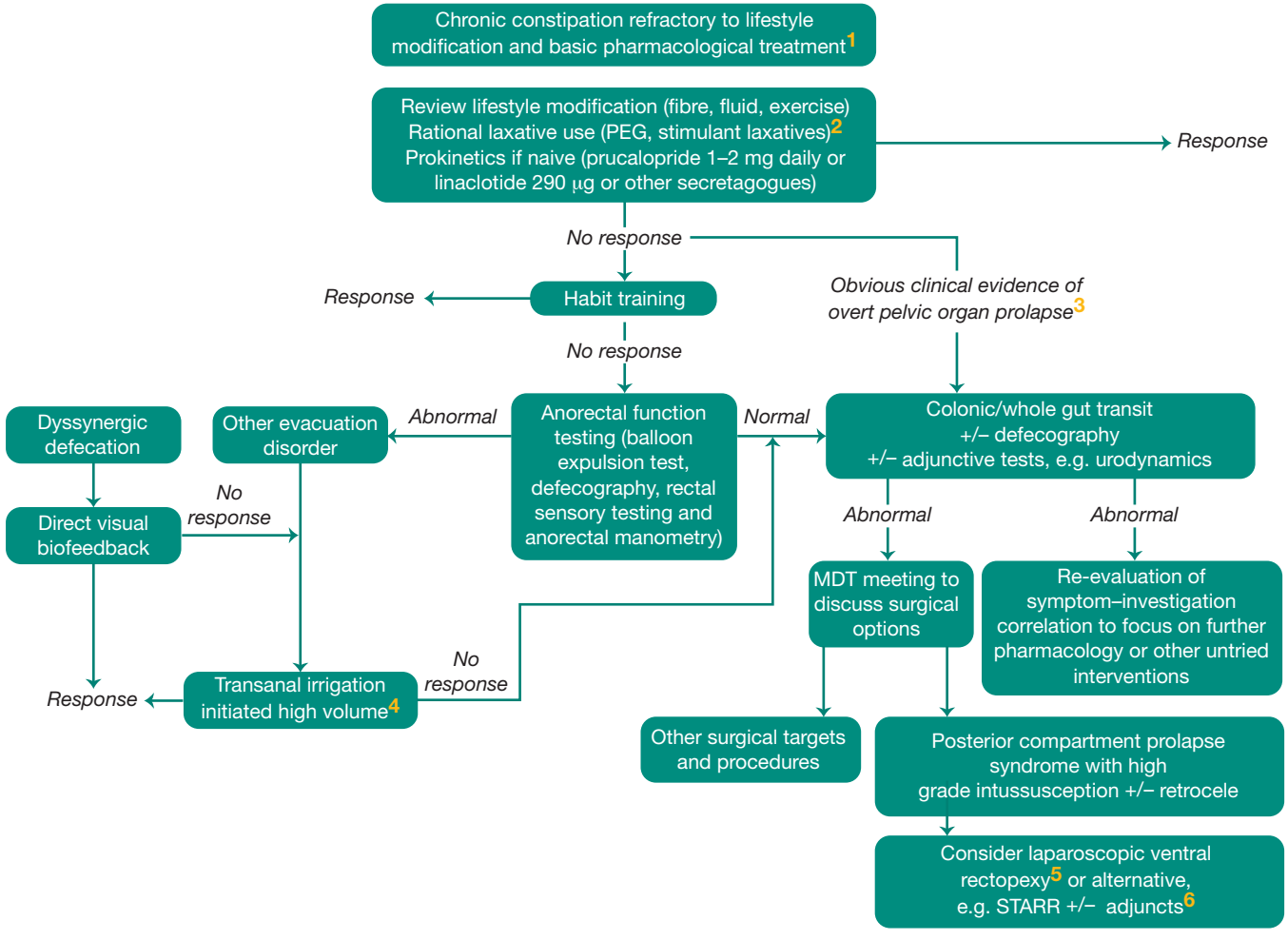

Figure 73.11 Algorithm of chronic constipation management. MDT, multidisciplinary team; PEG, polyethylene glycol. 1, alarm features excluded and secondary causes treated appropriately; 2, in constipation-predominant irritable bowel syndrome, consider antispasmodics or neuromodulators in case constipation improves but abdominal pain persists and is dominant symptom; 3, examples of overt prolapse include anterior (stage 3 cystocele), middle (stage 3 rectocele, uterovaginal prolapse) and posterior compartments (grade IV/V intussusception); 4, unless patient preference for low volume or specific contraindications to high volume; 5, may reduce specific symptoms but not have overall effect on quality of life; 6, common adjuncts include sacrocolpopexy, hysterectomy, transvaginal tape and cystocele repair.

drugs. These drugs are successful in a proportion of patients but do have some unwanted side effects (that the patient should be warned about). All drugs should be tried daily for a minimum of 4 weeks before concluding that they are ineffective and the reactionary use of laxatives, i.e. in response to being constipated, rather than their preventative use, should be strongly discouraged.

The most common form of behavioural intervention is often described by the term 'habit training'. This involves optimising dietary patterns to maximise gastrocolic response and the morning clustering of colonic high-amplitude propagated contractions that propel contents towards the rectum for subsequent evacuation. Dietary advice to optimise intake of liquid and fibre is given as well as advice about frequency and length of toilet visits and posture (***Figure 73.12***). Patients are also instructed on basic gut anatomy and function and gain an appreciation of how psychological and social stresses may influence gut functioning. Simple pelvic floor and balloon expulsion exercises are often included. Such appointments also

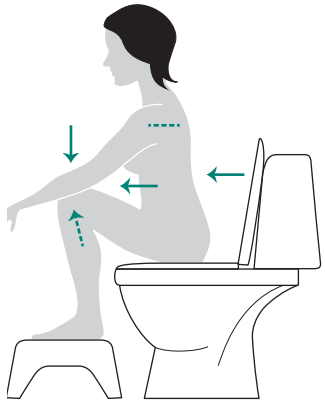

Figure 73.12 Correct posture for defecation.

offer an opportunity to further rationalise and monitor laxative therapy.

If this fails, there may be recourse to the specialist tests to assess colonic transit and also anorectal function (see ***Chapter 80***). Armed with the results of these tests, the patient may have a more targeted approach relative to their observed pathophysiology. One example of this approach is for patients with a condition termed 'dyssynergic defecation', where there is a failure to relax, or even paradoxical contraction of the pelvic floor muscles (especially puborectalis) during defecatory efforts. In such patients, instrument-based biofeedback learning techniques provide direct visual computer-based biofeedback of pelvic floor activity. The aim is to retrain the patient to appropriately contract abdominal and relax pelvic floor muscles during defecation with the patient receiving feedback of anal and pelvic floor muscle activity as recorded by surface electromyographic anal pressure sensors or digital examination by the therapist.

Transanal irrigation (TAI) may be used for any patient with an evacuation disorder when habit training and/or biofeedback have failed. A number of devices are available that administer a low (approximately 50–100 mL) or high volume (approximately 500 mL) of irrigant fluid into the rectum. The patient sits on the toilet to evacuate the fluid and faecal material.

Some patients with chronic refractory symptoms may seek a surgical solution to their problem. Surgical procedures can be broadly divided into those addressing dynamic structural problems of the pelvic floor (prolapse procedures), those that seek specifically to address slow-transit constipation and those that may have a role for both (***Summary box 73.8***).

Summary box 73.8

Surgical options in patients with chronic constipation

Prolapse procedures for dynamic structural causes of obstructed defecation

- Hitching procedures, e.g. rectopexy
- Rectal wall excisional procedures, e.g. stapled transanal rectal resection (STARR)
- Rectovaginal reinforcement procedures, e.g. posterior vaginal repair, intra-anal Delorme's procedure

Procedures for slow-transit constipation

- Colectomy and ileorectal anastomosis
- Other variants of subtotal colectomy

Procedures for refractory chronic constipation in general

- Stoma: ileostomy or colostomy
- ACE procedures
- Neuromodulation

All surgery should be undertaken in the knowledge that none of the above-listed operations is perfect. All represent a trade-off between benefits and short-term harms and poor long-term functional outcomes. On this basis, the following are essential requirements before surgery is undertaken:

- pathophysiological findings from specialist tests concur with the symptomatology and findings on clinical examination;
- conservative (non-surgical) treatment options have been tried;
- the patient's case has been reviewed at a multidisciplinary team (MDT) meeting and surgery recommended;
- the patient has been consented in the very clear knowledge of the range of possible outcomes;
- surgery is undertaken in a centre with expertise in managing functional conditions.

The range of procedures for rectal prolapse are covered in detail in ***Chapter 79***. Those primarily targeting the intestine are covered briefly here.

Colectomy

Colectomy is a radical and clearly irreversible final solution for patients with refractory slow-transit constipation. Its use should be very highly selective, not least because it is not actually a solution for many patients even when the surgery itself passes without complication. Removal of the whole colon with ileorectal anastomosis (as performed for inflammatory bowel disease) is best studied; subtotal resections with ileosigmoid or caecorectal anastomosis are alternatives. Outcomes vary greatly and are often compromised by early problems of ileus and a higher than expected rate of adhesional small bowel obstruction. Later problems include ongoing constipation and obstructive symptoms, diarrhoea and urgency, abdominal pain and bloating. Embarking on this procedure requires very careful MDT review, documentation of generalised slow-transit constipation and exclusion of a long list of relative contraindications.

Stoma

A stoma may be used as a definitive procedure, as a guide to further treatment or as salvage from a failed or complicated prior surgical intervention. There are few published data to support evidence-based use; however, an ileostomy may be employed as a guide to colectomy with subsequent resection avoided if ileostomy output is unsatisfactorily high or symptoms such as pain and bloating are untouched by diversion. As a definitive procedure, there is little evidence in adults to guide the choice of ileostomy or colostomy; however, it is generally considered that slow-transit constipation is unsatisfactorily treated by colostomy.

Anterograde colonic enema procedures

The formation of a conduit to introduce irrigant into the colon is best established in children and in patients with neurological disease. A variety of methods have been proposed to access the caecum either directly, e.g. with a Chait tube caecostomy, or indirectly via the appendix (appendicostomy). The latter is almost certainly preferable although only possible when the

Edmond Delorme, 1847–1929, French military surgeon and Professor of Surgery, Val-de-Grace Military Hospital, Paris, France.
Peter Graham Chait, contemporary, radiologist, Toronto, Canada.

native appendix is still present and the patient is not obese. The appendix can be reversed (Malone anterograde continent enema technique) or used in its native orientation (much simpler). Outcomes in adults with chronic constipation are variable but generally this is a good option in patients considering colectomy or stoma as the only alternative.

Neuromodulation

The attraction of being able to treat chronic constipation with a minimally invasive and safe approach such as sacral neuromodulation is supported by research data showing that stimulation improves motility and also some observational data. It is now clear from randomised trials that it has no role for slow-transit constipation but it may yet have a place in modifying anorectal function in some patients with severe functional syndromes leading to obstructed defecation (as it does for the bladder).

Irritable bowel syndrome

Surgery has no role in treating IBS. Nevertheless, patients with chronic abdominal pain and a change in their bowels are very common in surgical clinics and all surgeons should at least have a passing familiarity with a disorder that is a source of misery to millions of people worldwide.

Definitions

IBS is a functional bowel disorder characterised by abdominal pain or discomfort, stool irregularities and bloating. The term replaced nineteenth century descriptions such as 'irritable' or 'spastic' colon in 1979 to reflect the fact that the colon is not the only site of the problem. Diagnostic criteria have evolved to the now used Rome IV Foundation definition:

> ***Recurrent abdominal pain on average at least 1 day/week in the last 3 months, associated with two or more of three criteria: (1). related to defecation; (2). associated with a change in the frequency of stool and (3). associated with a change in the form (appearance) of stool. These criteria should be fulfilled for the last 3 months with symptom onset at least 6 months prior to diagnosis.***

The change in frequency and form of the stool dictates subdivisions of IBS into constipation-predominant (IBS-C), diarrhoea-predominant (IBS-D) and mixed (IBS-M) subclasses (***Figure 73.13***).

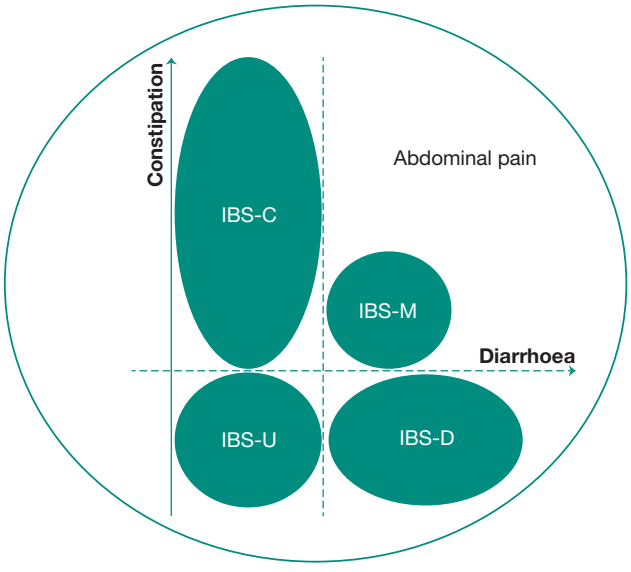

Figure 73.13 Irritable bowel syndrome (IBS) subtypes according to the Rome criteria. All patients have abdominal pain but subtypes vary according to bowel form at presentation such as to meet criteria for IBS with constipation (IBS-C), IBS with diarrhoea (IBS-D), mixed-type IBS (IBS-M) and unsubtyped (IBS-U).

Aetiology and risk factors

Regardless of exact definition, the cardinal symptoms of chronic abdominal pain and 'deranged digestion' favour a 'biopsychosocial model' (***Figure 73.14***) that encompasses the role of stressful life events and brain–gut interactions in symptom generation. Several common life events are particularly well documented; these include postinfective IBS, where a seemingly discrete attack of gastroenteritis (viral, bacterial or otherwise) is followed by chronic ongoing symptoms; physical and/or sexual abuse (and neglect); surgery; and trauma. One implication of the model is that IBS has much overlap with other medical conditions that have similar or nearly identical biopsychosocial determinants (***Summary box 73.9***).

Summary box 73.9

IBS-associated comorbidities

General

- Fibromyalgia syndrome
- Chronic fatigue syndrome
- Chronic pelvic pain, chronic prostatitis and bladder pain syndromes
- Chronic back pain
- Migraines
- Depression
- Anxiety
- Somatisation
- Sleep disturbance

Gastrointestinal disorders[a]

- Eating disorders
- Dyssynergic defecation
- Levator ani syndrome and proctalgia fugax
- Food intolerances

[a]The overlap of IBS with other Rome-defined functional gastrointestinal disorders should also be noted, including functional dyspepsia and functional constipation.

Patrick Malone, contemporary, surgeon, Southampton, UK.

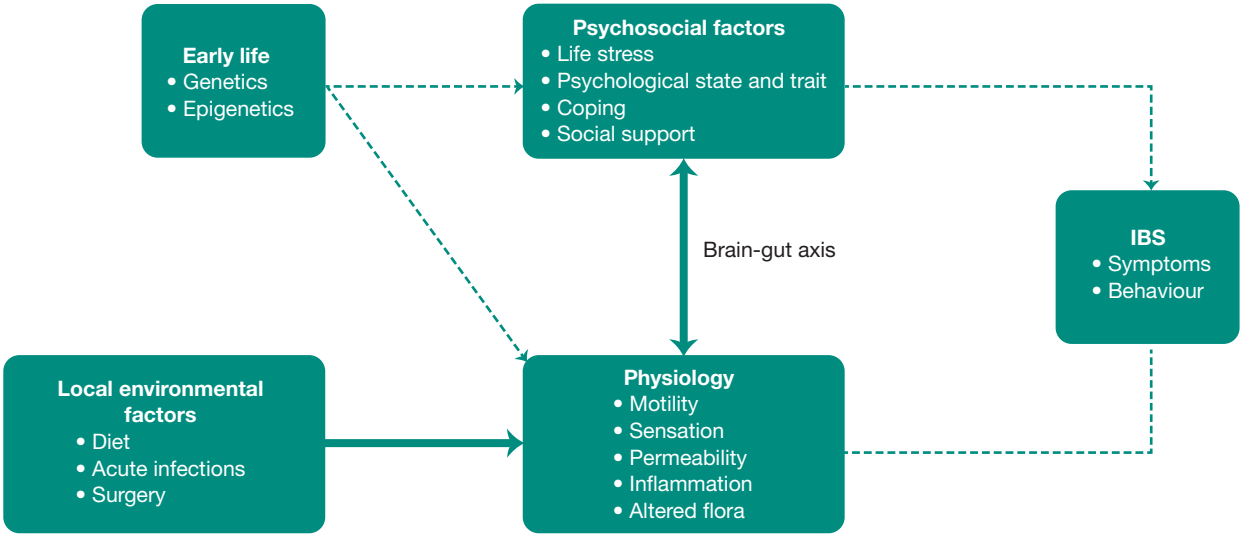

Figure 73.14 Biopsychosocial model of irritable bowel syndrome (IBS). The scheme is a conceptualisation of the pathogenesis and clinical expression of IBS showing interrelationships between various risk factors and changes in physiology.

Diagnosis

Clinical history

Besides symptoms required by the diagnostic criteria, other symptoms may be present. Common associated symptoms include bloating (very common), straining at defecation, excessive flatulence and postprandial indigestion. A history of precipitating events (as per the model) and of comorbidities (***Summary box 73.7***) should also be sought to support the diagnosis. The patient may also have a history of multiple operations, which on reflection may have been directed to chronic abdominal pain, e.g. appendicectomy, cholecystectomy or hysterectomy.

Clinical examination

Physical examination helps to reassure patients and also to exclude another organic cause for symptoms. However, abdominal examination rarely discloses a specific diagnosis (abdominal tenderness is often present but non-specific); the absence of objective findings supports a diagnosis of IBS. A digital rectal examination may identify patients with dyssynergic defecation and other causes of constipation.

Investigations

There are no valid laboratory biomarkers of IBS. Routine blood panels, including inflammatory markers, are generally

TABLE 73.7 Treatments for irritable bowel syndrome.

Nutrition	Increased (constipation) or reduced (bloating) fibre
	Gluten-free diet (especially if equivocal diagnosis of coeliac disease)
	FODMAP diet
	Probiotics
	Consider dietary supplements, prebiotics
Drugs	Antispasmodics: peppermint oil, hyoscine butylbromide (Buscopan)
	Laxatives, e.g. stool softeners, osmotic and stimulant (avoid lactulose because of bloating and pain)
	Antidiarrhoeals: loperamide (μ-opioid receptor agonist); 5-HT_3 receptor antagonists, such as alosetron, ondansetron
	Motility accelerants, e.g. linaclotide (guanylyl cyclase C agonist), prucalopride (5-HT_4 receptor agonist)
	Low-dose antidepressants: tricyclics and selective serotonin reuptake inhibitors
	Manipulation of the microbiota by non-absorbable antibiotics, e.g. rifaximin
	Neuromodulators, e.g. gabapentin and pregabalin
Psychotherapy	Cognitive–behavioural therapy
	Gut-directed hypnosis
	Guided self-help interventions

5-HT, 5-hydroxytryptamine; FODMAP, fermentable oligosaccharides, disaccharides, monosaccharides and polyols.

performed to reassure that there are no indicators of organic disease, e.g. cancer, inflammatory bowel disease or diverticular disease. Specific tests include serological tests for coeliac disease, faecal calprotectin and stool microbiology in cases of diarrhoea predominance. Invasive procedures are generally not warranted unless alarm features are present that mandate endoscopy. That noted, it is quite common practice to perform colonoscopy, not least to reassure the patient that their chronic symptoms do not have an organic basis. In patients with IBS-D, colonoscopy with random biopsies is warranted to exclude microscopic colitis. Other tests that may be relevant include (75Se-homocholic acid taurine [^{75}SeHCAT] test or serum serum 7-α-hydroxy-4-cholesten-3-one (C4) levels) for bile salt malabsorption, breath testing for carbohydrate malabsorption, gastrointestinal physiology for constipation and upper gastrointestinal endoscopy for associated dyspeptic symptoms.

Management

Only a fraction of patients with IBS-like symptoms seek medical care and most will initially consult primary care physicians for their symptoms. The factors that drive this consultation are symptom severity, especially pain, and concerns that symptoms might indicate an underlying severe disease, e.g. cancer. Therefore, in many cases, the doctor's role is to exclude diseases that can mimic IBS symptoms by relevant investigations such as endoscopy.

When a positive diagnosis of IBS has been made, management requires an integrated approach, including education, reassurance, dietary alterations, pharmacotherapy and behavioural or psychological interventions/support. The initial treatment strategy should be based on predominant symptoms and includes antispasmodics for abdominal pain, antidiarrhoeals for IBS-D and laxatives for IBS-C, whereas nutritional interventions and psychotherapy can be used in all subtypes. ***Table 73.7*** provides a list of potential management strategies for IBS. This list is not all encompassing, nor does it provide weighting to one treatment over another in terms of effectiveness in clinical trials. Some treatments are popular, e.g. low-dose antidepressants but such use is off-label; others may be tried over the counter by patients, e.g. prebiotics, although there is no trial evidence.

A key point in the management of IBS rests with notable exclusions from ***Table 73.7***. Thus the table makes no reference to standard analgesics and surgery. Opioid analgesia should be avoided in IBS because the further disturbance to motility worsens the prognosis and in extreme use can lead to narcotic bowel syndrome (an opioid-induced state of hyperalgesia whose main driver is the activation of glial cells). Surgery has a well-documented association with symptom onset of IBS (cholecystectomy, appendicectomy, hysterectomy and back surgery); further surgery leads not only to greater potential visceral sensitisation (via injury) but also serves to confuse subsequent diagnosis, e.g. adhesional versus functional cause for symptoms. There is also a body of evidence to suggest that surgery perpetuates a search for an 'organic' diagnosis that hinders patient acceptance and adaption to their chronic problem. For the surgeon, the key is to exclude any surgical cause of pain and then prevent further harm by avoiding surgery.

SUMMARY

Functional intestinal disorders range from the very common – constipation and IBS – through to the very rare, e.g. various genetic and familial neuropathies and myopathies causing IPO. The surgeon will almost certainly encounter acute problems such as POI and ACPO. This chapter provides an overview that can be supplemented by the recommended further reading.

FURTHER READING

Bharucha A, Knowles CH. Chronic constipation. In: Sagar PM, Hill AG, Knowles CH *et al.* (eds). *Keighley & Williams' surgery of the anus, rectum and colon*, 4th edn. Boca Raton, FL: Taylor & Francis, 2019: 305–46.

Enck P, Aziz Q, Barbara G *et al.* Irritable bowel syndrome. *Nat Rev Dis Primers* 2016; **2**: 16014.

van Bree SHW, Nemethova A, Cailotto C *et al.* New therapeutic strategies for postoperative ileus. *Nat Rev Gastroenterol Hepatol* 2012; **9**: 675–83.